

# Hypoglossal Nerve Stimulator Implantation in an Adolescent With Down Syndrome and Sleep Apnea

Gillian R. Diercks, MD,<sup>a,b</sup> Donald Keamy, MD, MPH,<sup>a,b,c</sup> Thomas Bernard Kinane, MD,<sup>c,d</sup> Brian Skotko, MD, MPP,<sup>d,e</sup> Allison Schwartz, MD,<sup>d,e</sup> Ellen Grealish, RPSGT, REEGT,<sup>c</sup> John Dobrowski, MD,<sup>a,b</sup> Ryan Soose, MD,<sup>f</sup> Christopher J. Hartnick, MD<sup>a,b</sup>

Obstructive sleep apnea (OSA) is more common in children with Down syndrome, affecting up to 60% of patients, and may persist in up to 50% of patients after adenotonsillectomy. These children with persistent moderate to severe OSA require continuous positive airway pressure, which is often poorly tolerated, or even tracheotomy for severe cases. The hypoglossal nerve stimulator is an implantable device that produces an electrical impulse to the anterior branches of the hypoglossal nerve, resulting in tongue protrusion in response to respiratory variation. It is an effective treatment of sleep apnea in select adult patients because it allows for alleviation of tongue base collapse, improving airway obstruction. Herein we describe the first pediatric hypoglossal nerve stimulator implantation, which was performed in an adolescent with Down syndrome and refractory severe OSA (apnea hypopnea index [AHI]: 48.5 events/hour). The patient would not tolerate continuous positive airway pressure and required a long-standing tracheotomy. Hypoglossal nerve stimulator therapy was well tolerated and effective, resulting in significant improvement in the patient's OSA (overall AHI: 3.4 events/hour; AHI: 2.5–9.7 events/hour at optimal voltage settings depending on sleep stage and body position). Five months after implantation, the patient's tracheotomy was successfully removed and he continues to do well with nightly therapy.

Obstructive sleep apnea (OSA) affects up to 2% to 5.7% of the general pediatric population and is associated with adverse behavior and quality of life, as well as long-term cardiopulmonary system complications.<sup>1,2</sup> Down syndrome (DS) is the most common chromosomal disorder, with an incidence of ~14.2 per 10 000 live births.<sup>3</sup> Patients with DS have a higher incidence of OSA than the general pediatric population, with rates of 30% to 80%, resulting in increased morbidity and decreased quality of life for affected individuals.<sup>4</sup> In children, adenotonsillar hypertrophy is often a contributing factor to OSA, and

adenotonsillectomy (T&A) is the initial treatment of choice. Children with DS often undergo T&A for OSA; however, up to 67% will have persistent obstructive sleep patterns, which are attributed to anatomic and physiologic differences in this population, including reduced muscular tone, macroglossia, maxillary hypoplasia, and lingual tonsil hypertrophy.<sup>5,6</sup> These children often require positive-pressure airway support (continuous positive airway pressure [CPAP] or bilevel positive airway pressure), oromaxillofacial surgery, oxygen, or, in severe cases, tracheotomy for persistent airway obstruction<sup>7</sup>; these treatments, although effective when

## abstract

<sup>a</sup>Department of Otolaryngology, Massachusetts Eye and Ear Infirmary, Boston, Massachusetts; Departments of <sup>b</sup>Otology and Laryngology and <sup>c</sup>Pediatrics, Harvard Medical School, Boston, Massachusetts; <sup>d</sup>Pediatric Sleep Associates and <sup>e</sup>Down Syndrome Program, Division of Medical Genetics, Department of Pediatrics, Massachusetts General Hospital, Boston, Massachusetts; and <sup>f</sup>Department of Otolaryngology, University of Pittsburgh, Pittsburgh, Pennsylvania

This study was approved under investigational device exemption (IDE) G140209.

Drs Diercks, Keamy, Kinane, Skotko, Schwartz, Dobrowski, Soose, and Hartnick were involved in the planning and execution of the study and critically reviewed and revised the manuscript; Ms Grealish was involved in the study design and the execution and interpretation of study-related polysomnograms; and all authors approved the final manuscript as submitted.

This trial has been registered at [www.clinicaltrials.gov](http://www.clinicaltrials.gov) (identifier NCT2344108).

**DOI:** 10.1542/peds.2015-3663

Accepted for publication Feb 11, 2016

Address correspondence to Christopher J. Hartnick, MD, Massachusetts Eye and Ear Infirmary, 243 Charles St, Boston, MA 02114. E-mail: [christopher\\_hartnick@meei.harvard.edu](mailto:christopher_hartnick@meei.harvard.edu)

PEDIATRICS (ISSN Numbers: Print, 0031-4005; Online, 1098-4275).

Copyright © 2016 by the American Academy of Pediatrics

**FINANCIAL DISCLOSURE:** Inspire Medical Systems provided technical support and provided the nerve stimulators used in this study free of charge. Dr Skotko occasionally consults on the topic of Down syndrome through Gerson Lehrman Group; he has a R40 grant to study obstructive sleep apnea in

**To cite:** Diercks GR, Keamy D, Kinane TB, et al. Hypoglossal Nerve Stimulator Implantation in an Adolescent With Down Syndrome and Sleep Apnea. *Pediatrics*. 2016;137(5):e20153663

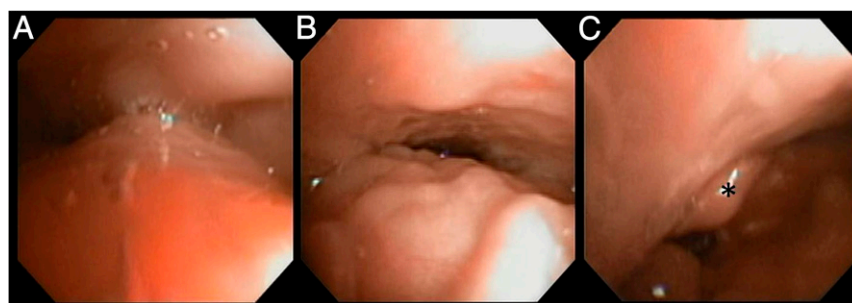
used consistently, are often poorly tolerated.

The hypoglossal nerve stimulator (Inspire Medical Systems, Maple Grove, MN) is an implantable device that senses respiratory patterns and delivers electrical impulses to the anterior branches of the hypoglossal nerve during inspiration, resulting in stimulation of the genioglossus, which protrudes the tongue and can alleviate nocturnal upper airway obstruction.<sup>8</sup> This device has been shown to be effective in neurotypical adults with moderate to severe OSA with an apnea hypopnea index (AHI) <50 events/hour and a BMI <32, and without circumferential airway collapse at the level of the velopharynx.<sup>9,10</sup> The device was recently approved for commercial use in adult patients meeting select criteria.

Given the anatomic considerations in children with DS and the high incidence of persistent upper airway obstruction after T&A, we developed a pilot study to evaluate the efficacy and safety of hypoglossal nerve stimulator implantation in adolescents and young adults with DS and persistent OSA. This study was reviewed and approved by the institutional review board at our facility as well as by the Food and Drug Administration, which issued an investigational device exemption. Here we present the preliminary results and 5-month follow-up of the first pediatric patient implanted with the device.

### CASE REPORT

A 14-year-old boy with translocation DS and a long-standing tracheotomy due to severe OSA despite previous T&A and lingual tonsillectomy, well known to our institution, was selected as the first implant candidate. Before the placement of a tracheotomy, CPAP therapy had been trialed and was not tolerated. As an older child, CPAP therapy was trialed



**FIGURE 1**

Pattern of airway obstruction identified during drug-induced sleep endoscopy. A, Complete anteroposterior collapse at the velopharynx. B, Complete anteroposterior collapse at the tongue base. C, Complete anteroposterior collapse at the level of the epiglottis, denoted by the asterisk (\*), which can be seen retroflexed and opposing the posterior pharyngeal wall.

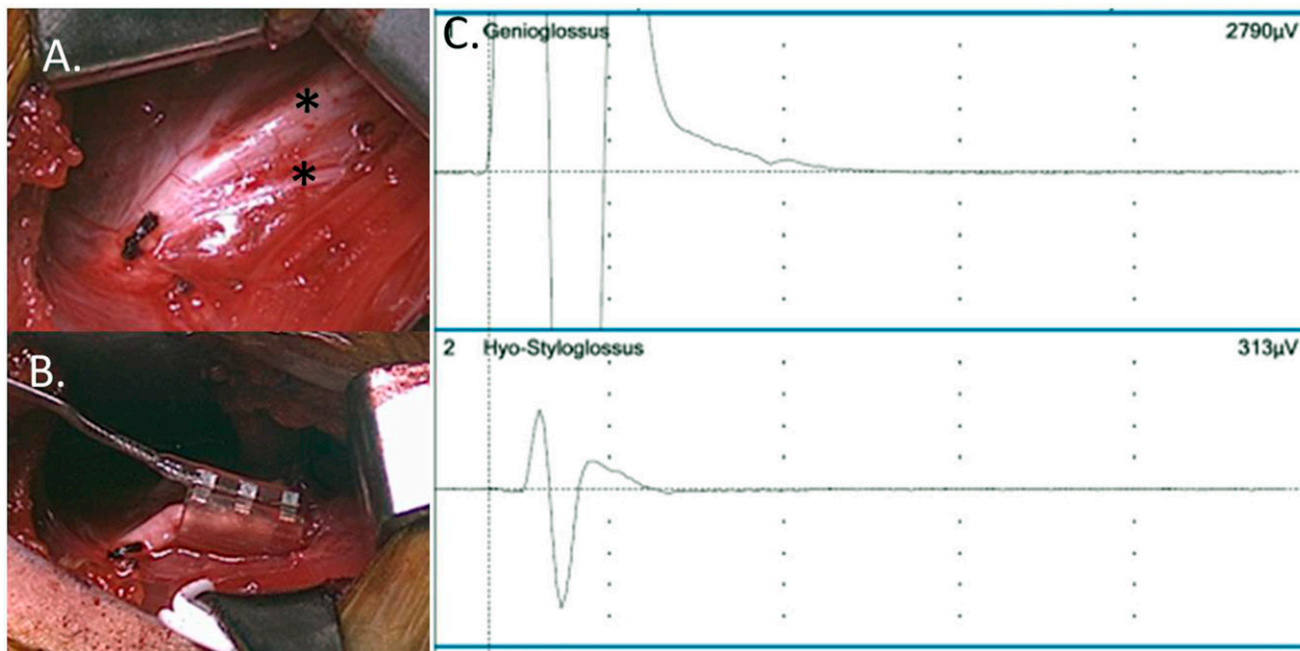
again with the tracheotomy capped to determine if the patient could be decannulated; again, the patient was unable to tolerate therapy.

The patient attended school regularly and was cooperative with daily tracheotomy care and physical examinations. In addition, his family reported that he was able to express himself and localize any sources of discomfort. Like many children with DS, the patient had a ventricular septal defect repaired during the first year of life. He also had a history of aspiration pneumonia as a child, which resolved after gastrostomy tube placement, Nissen fundoplication, and thickening of liquids taken by mouth. The patient had a history of reactive airway disease, which was well controlled with medication. His tracheotomy tube was capped during the day; however, he required that it be uncapped at night due to severe upper airway obstruction.

Before implantation, the patient underwent a series of tests to verify he met study inclusion criteria. His BMI was noted to be 24.6 (~90th percentile, overweight but not obese). Preoperative polysomnography, which was performed ~4 months before implantation and scored by using American Academy of Sleep Medicine pediatric standards,<sup>11</sup> revealed a capped AHI of 48.5 events/hour, an uncapped AHI of 0.9 events/

hour, and a central apnea index of 2.4 events/hour. He had no rapid eye movement (REM) sleep, likely due to the severity of his OSA. Four months before implantation, the patient also underwent drug-induced sleep endoscopy, which is an airway endoscopy performed under sedation with dexmedetomidine and propofol to simulate airway anatomy during sleep, to identify the regions and anatomic patterns responsible for upper airway obstruction. Drug-induced sleep endoscopy revealed evidence of complete anterior-posterior airway collapse at the level of the velopharynx, tongue base, and epiglottis (Fig 1). Study inclusion criteria, which were based on previous adult studies of hypoglossal nerve stimulator implantation, required a BMI <32, an AHI <50 events/hour with <25% due to central events, and no evidence of circumferential collapse of the airway at the level of the velopharynx. The patient was believed to be an excellent candidate for implantation and informed consent was obtained.

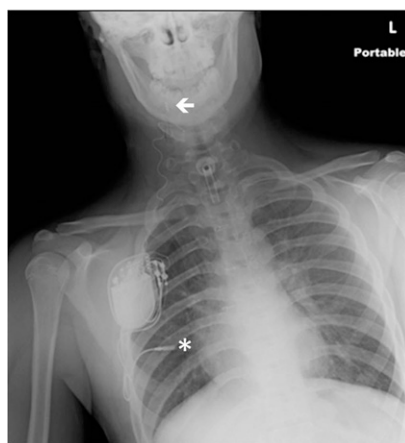In April 2015, the patient underwent uneventful placement of the first pediatric hypoglossal nerve stimulator. He received preoperative nasal mupirocin and chlorhexidine rinses due to a previous history of methicillin-resistant *Staphylococcus aureus* carriage, as well as vancomycin and ampicillin/sulbactam



**FIGURE 2**

Intraoperative electrode placement and system validation. A, The hypoglossal nerve was dissected anteriorly until lateral and anterior branches (\*) were identified and isolated. B, The electrode cuff was placed around anterior branches. C, Selective stimulation of the genioglossus by anterior branches was confirmed with electromyographic testing. Although some stimulation to the retrusor muscles is unavoidable (313  $\mu$ V), stimulation of the protrusor muscles was much more pronounced (2790  $\mu$ V).

intraoperatively to reduce the risk of perioperative wound infection. The impulse generator, pleural sensing electrode, and hypoglossal nerve stimulation electrode were surgically implanted while hypoglossal nerve activity was monitored by using continuous electromyogenic potential recording. The technique of hypoglossal nerve stimulator implantation has been described previously.<sup>12</sup> Intraoperative testing confirmed exclusion of tongue retrusor muscle activity (Fig 2), and baseline system validation was performed at 0.6 V. Postoperative portable chest radiography revealed the nerve stimulator to be in an excellent position (Fig 3). The patient's postoperative discomfort was minimal and well controlled with acetaminophen and without the need for narcotic analgesics. He was discharged from the hospital on the morning of postoperative day 1 and continued to uncap his tracheotomy at night.



**FIGURE 3**

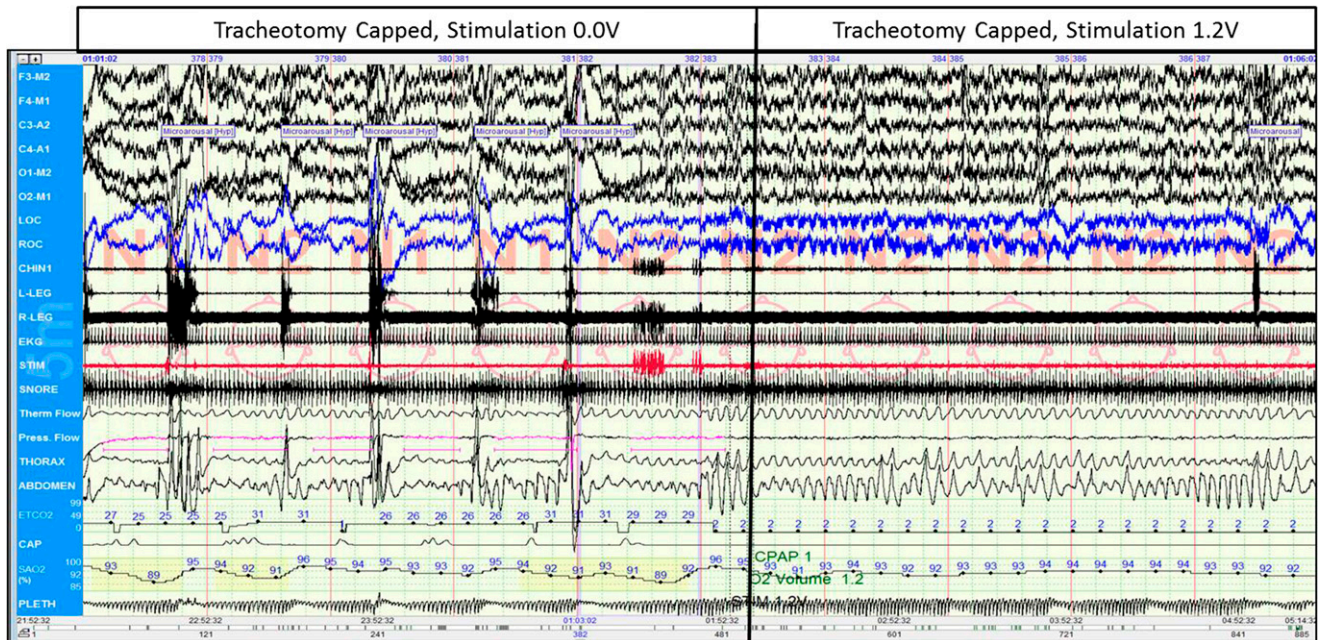
Postoperative chest radiograph showing excellent placement of the impulse generator over the right chest, pleural sensing electrode (\*), and stimulation electrode (arrow). L, left.

One month after implantation, the patient returned to clinic where the device was activated and initial threshold testing was performed. The device was then turned off and reactivated that evening during a polysomnogram. Polysomnography revealed that with the tracheotomy

uncapped and with the system activated, the patient had improved and regular nasal airflow. With the tracheotomy tube capped for a short duration without stimulation, the patient showed severe upper airway obstruction; however, with the system turned to 1.1 to 1.3 V, the patient's overall capped AHI was dramatically improved to 10.6 events/hour (Fig 4). Overnight, he entered into REM sleep, which accounted for 14% of total sleep time. He was discharged from the hospital the following morning to use the stimulator 8 hours/night at 1.3 V; the tracheotomy remained uncapped at night while the patient acclimated to stimulation.

One month after initial activation, the patient returned for an additional polysomnogram and voltage titration of his device. The patient's family reported no adverse events, and the patient tolerated nightly use of the device, which was corroborated by using weekly use questionnaires completed by the family as well as





**FIGURE 4**

Multichannel polysomnogram tracing with tracheotomy capped showing the transition between no stimulation and stimulation at 1.2 V. Notice the immediate resolution of apneas and hypopneas, associated desaturations, and regular arousals after the stimulator was activated. Legend key (top to bottom): F3-M2 to O2-M1, EEG leads; LOC and ROC, left and right electrooculograms, respectively; CHIN1, chin electromyogram (EMG); L-LEG and R-LEG, limb EMGs; EKG, electrocardiogram; STIM, filtered chin EMG to measure stimulator artifact; SNORE, upper airway sound recording; Therm Flow to Press Flow, airflow measured by thermistor and pressure transducers, respectively; THORAX to ABDOMEN, thoracic and abdominal effort measured by thoracoabdominal piezoelectric belts, respectively; ETCO<sub>2</sub> to CAP, end-tidal carbon dioxide, measured by capnography; SAO<sub>2</sub>, oxygen saturation; PLETH, pulse waveform from Sa<sub>o</sub><sub>2</sub> sensor. Hyp, hypopnea.

**TABLE 1** Capped Sleep Study Results Before and After System Activation

	Preimplantation PSG	Activation PSG	One Month After Activation PSG
System settings, V	N/A	1.1–1.3	1.3–1.5
Capped AHI, events/h	48.5	10.6 <sup>a</sup>	2.5–21.1 <sup>b</sup>

N/A, not applicable ; PSG, polysomnogram.

<sup>a</sup> Overall AHI while tracheotomy capped.

<sup>b</sup> Overall AHI while tracheotomy was capped with device activated at 1.3–1.5 V was 9.7 events/hour. At 1.3 V the AHI was 21.1 events/hour, at 1.4 V the AHI was 3.7 events/hour, at 1.5 V the overall AHI was 3.4 events/hour (range: 2.5–9.7 events/hour depending on sleep stage and body position).

a computerized log built into the device. The second polysomnogram revealed persistent excellent response to stimulation, with an overall capped AHI of 9.7 events/hour with the device set at 1.3 to 1.5 V. REM sleep accounted for 13.6% of total sleep time while the device was activated. The device was titrated to 1.5 V, which reduced his AHI into the mild–moderate range (AHI: 2.5–9.7 events/hour, depending on sleep stage and body position, with overall an AHI of 3.4 events/hour) (Table 1). The patient’s family requested to increase the activation time to

9 hours/night. The patient was advised to continue uncapping his tracheotomy at night.

Approximately 4 months after activation, the patient underwent bronchoscopy, which revealed no evidence of granulation tissue that would preclude removal of his tracheotomy tube. Given his remarkable response to upper airway stimulation, as well as potential risks of persistent long-term tracheotomy, after discussion with his family the decision was made to proceed with decannulation. After admission for a nocturnal tracheotomy cap

trial, which the patient successfully completed with his nerve stimulator activated at 1.5 V, his tracheotomy was successfully removed. The patient continues to do well. He will have additional polysomnograms 6 and 12 months after implantation as part of the pilot study.

## DISCUSSION

This case report presents preliminary results of, to our knowledge, the first pediatric hypoglossal nerve stimulator ever implanted. We show that, in a carefully selected adolescent patient with DS, the nerve stimulator was effective in relieving upper airway obstruction and was well tolerated. Further long-term study is needed to determine if effectiveness and stimulation settings are stable over time; however, previous studies in adult patients have shown a persistent response.<sup>10</sup> In addition, implantation of additional pediatric

patients is needed to determine if the nerve stimulator is effective and safe for other children with DS and OSA, particularly those who do not have a tracheotomy and are reliant on CPAP.

Hypoglossal nerve stimulation represents an important step toward alleviating upper airway obstruction in pediatric patients with refractory OSA after T&A. However, there is concern about implanting small children and adolescents who have not yet undergone puberty, because growth has the potential to displace device electrodes; the ideal age for implantation has not been established. In addition, like other

implantable devices that rely on battery power to generate electrical impulses, the implantable pulse generator will need to be replaced approximately every decade due to limited battery capacity, which raises additional questions about safety. The risks and benefits of implantation will need to be considered moving forward as more data are gathered on initial pediatric implant recipients.

#### ACKNOWLEDGMENTS

We acknowledge our colleagues Luke Lozier, Quan Ni, and

Michael Coleman at Inspire Medical Systems for technical support and guidance provided during the planning and execution of this project.

#### ABBREVIATIONS

AHI: apnea hypopnea index  
CPAP: continuous positive airway pressure  
DS: Down syndrome  
OSA: obstructive sleep apnea  
REM: rapid eye movement  
T&A: adenotonsillectomy

patients with Down syndrome from the Health Resources and Services Administration's Maternal and Child Health Bureau and receives remuneration from Down syndrome nonprofit organizations for speaking engagements and associated travel expenses; he also receives annual royalties from Woodbine House, Inc, for the publication of his book, *Fasten Your Seatbelt: A Crash Course on Down Syndrome for Brothers and Sisters*. The other authors have indicated they have no financial relationships relevant to this article to disclose.

**FUNDING:** Inspire Medical Systems provided the devices used in this study free of charge. Massachusetts Eye and Ear Infirmary staff and facilities waived professional, facility, and operating room fees for this study.

**POTENTIAL CONFLICT OF INTEREST:** Dr Skotko is occasionally asked to serve as an expert witness for legal cases in which Down syndrome is discussed; the other authors have indicated they have no potential conflicts of interest to disclose.

#### REFERENCES

1. Section on Pediatric Pulmonology, Subcommittee on Obstructive Sleep Apnea Syndrome. American Academy of Pediatrics. Clinical practice guideline: diagnosis and management of childhood obstructive sleep apnea syndrome. *Pediatrics*. 2002;109(4):704–712
2. Marcus CL, Brooks LJ, Draper KA, et al; American Academy of Pediatrics. Diagnosis and management of childhood obstructive sleep apnea syndrome. *Pediatrics*. 2012;130(3):576–584
3. Mai CT, Kucik JE, Isenburg J, et al; National Birth Defects Prevention Network. Selected birth defects data from population-based birth defects surveillance programs in the United States, 2006 to 2010: featuring trisomy conditions. *Birth Defects Res A Clin Mol Teratol*. 2013;97(11):709–725
4. Breslin J, Spanò G, Bootzin R, Anand P, Nadel L, Edgin J. Obstructive sleep apnea syndrome and cognition in Down syndrome. *Dev Med Child Neurol*. 2014;56(7):657–664
5. Sedaghat AR, Flax-Goldenberg RB, Gayler BW, Capone GT, Ishman SL. A case-control comparison of lingual tonsillar size in children with and without Down syndrome. *Laryngoscope*. 2012;122(5):1165–1169
6. Levanon A, Tarasiuk A, Tal A. Sleep characteristics in children with Down syndrome. *J Pediatr*. 1999;134(6):755–760
7. Shete MM, Stocks RM, Sebelik ME, Schoumacher RA. Effects of adenotonsillectomy on polysomnography patterns in Down syndrome children with obstructive sleep apnea: a comparative study with children without Down syndrome. *Int J Pediatr Otorhinolaryngol*. 2010;74(3):241–244
8. Schwartz AR, Bennett ML, Smith PL, et al. Therapeutic electrical stimulation of the hypoglossal nerve in obstructive sleep apnea. *Arch Otolaryngol Head Neck Surg*. 2001;127(10):1216–1223
9. Van de Heyning PH, Badr MS, Baskin JZ, et al. Implanted upper airway stimulation device for obstructive sleep apnea. *Laryngoscope*. 2012;122(7):1626–1633
10. Strollo PJ Jr, Soose RJ, Maurer JT, et al; STAR Trial Group. Upper-airway stimulation for obstructive sleep apnea. *N Engl J Med*. 2014;370(2):139–149
11. American Academy of Sleep Medicine. American Academy of Sleep Medicine manual for the scoring of sleep and associated events: rules, terminology and technical specifications. version 2.0. Available at: [www.aasmnet.org/scoringmanual](http://www.aasmnet.org/scoringmanual). Accessed January 5, 2016
12. Maurer JT, Van de Heyning P, Lin H-S, et al. Operative technique of upper airway stimulation: an implantable treatment of obstructive sleep apnea. *Operative Techniques in Otolaryngology*. 2012;23(3):227–233

## Hypoglossal Nerve Stimulator Implantation in an Adolescent With Down Syndrome and Sleep Apnea

Gillian R. Diercks, Donald Keamy, Thomas Bernard Kinane, Brian Skotko, Allison Schwartz, Ellen Grealish, John Dobrowski, Ryan Soose and Christopher J. Hartnick

*Pediatrics*; originally published online April 28, 2016;

DOI: 10.1542/peds.2015-3663

<b>Updated Information &amp; Services</b>	including high resolution figures, can be found at: <a href="/content/early/2016/04/26/peds.2015-3663.full.html">/content/early/2016/04/26/peds.2015-3663.full.html</a>
<b>References</b>	This article cites 11 articles, 2 of which can be accessed free at: <a href="/content/early/2016/04/26/peds.2015-3663.full.html#ref-list-1">/content/early/2016/04/26/peds.2015-3663.full.html#ref-list-1</a>
<b>Subspecialty Collections</b>	This article, along with others on similar topics, appears in the following collection(s): <b>Surgery</b> <a href="/cgi/collection/surgery_sub">/cgi/collection/surgery_sub</a> <b>Sleep Medicine</b> <a href="/cgi/collection/sleep_medicine_sub">/cgi/collection/sleep_medicine_sub</a>
<b>Permissions &amp; Licensing</b>	Information about reproducing this article in parts (figures, tables) or in its entirety can be found online at: <a href="/site/misc/Permissions.xhtml">/site/misc/Permissions.xhtml</a>
<b>Reprints</b>	Information about ordering reprints can be found online: <a href="/site/misc/reprints.xhtml">/site/misc/reprints.xhtml</a>

PEDIATRICS is the official journal of the American Academy of Pediatrics. A monthly publication, it has been published continuously since 1948. PEDIATRICS is owned, published, and trademarked by the American Academy of Pediatrics, 141 Northwest Point Boulevard, Elk Grove Village, Illinois, 60007. Copyright © 2016 by the American Academy of Pediatrics. All rights reserved. Print ISSN: 0031-4005. Online ISSN: 1098-4275.

American Academy of Pediatrics

DEDICATED TO THE HEALTH OF ALL CHILDREN™



# PEDIATRICS®

OFFICIAL JOURNAL OF THE AMERICAN ACADEMY OF PEDIATRICS

## **Hypoglossal Nerve Stimulator Implantation in an Adolescent With Down Syndrome and Sleep Apnea**

Gillian R. Diercks, Donald Keamy, Thomas Bernard Kinane, Brian Skotko, Allison Schwartz, Ellen Grealish, John Dobrowski, Ryan Soose and Christopher J. Hartnick  
*Pediatrics*; originally published online April 28, 2016;  
DOI: 10.1542/peds.2015-3663

The online version of this article, along with updated information and services, is located on the World Wide Web at:  
</content/early/2016/04/26/peds.2015-3663.full.html>

PEDIATRICS is the official journal of the American Academy of Pediatrics. A monthly publication, it has been published continuously since 1948. PEDIATRICS is owned, published, and trademarked by the American Academy of Pediatrics, 141 Northwest Point Boulevard, Elk Grove Village, Illinois, 60007. Copyright © 2016 by the American Academy of Pediatrics. All rights reserved. Print ISSN: 0031-4005. Online ISSN: 1098-4275.

American Academy of Pediatrics

DEDICATED TO THE HEALTH OF ALL CHILDREN™

